Percutaneous transluminal balloon angioplasty in the treatment of dialysis fistula dysfunction. Differences of vascular access

Tomasz NOWAK
Maciej LEWANDOWSKI
Andrzej MODRZEJEWSKI
Jarosław GORĄCY
Irmina KOSSUTH

Department of Cardiology Surgical
Head:
Prof. dr hab. n. med. Jarosław Kaźmierczak

Emergency Nursing Department
Pomeranian Medical University. Szczecin, Poland
Head:
Dr hab. n. med. Włodzimierz Majewski

Key words:
- dialysis fistula
- vascular access
- percutaneous transluminal angioplasty

Słowa kluczowe:
- przetoka dializacyjna
- dostęp naczyniowy
- przezskórna przezcewnikowa angioplastyka

Background: Percutaneous transluminal angioplasty of failing arteriovenous fistula is confirmed and recommended procedure in many cases. Our objective was to evaluate the outcome and safety of balloon angioplasty in dysfunction of dialysis fistula with using other than commonly used vascular access.

Material and Methods: We qualified 45 patients with dysfunction of haemodialysis fistula to angiography and then 37 patients to angioplasty if stenosis or thrombosis where diagnosed. Every angiography was began from femoral access. Procedure efficiency was evaluated by significant gain of lumen diameter in angiographic imaging and by properly-working fistula through continuous dialysis, what where observed in follow-up to 12 months. We were also trying to identify factors causing dysfunction and possibilities to prevent future dysfunction of dialysis fistula.

Results: Our results demonstrate that angiography and balloon angioplasty of failing dialysis fistula is well-efficient procedure with also high safety for patient. Two significant complications occurred during procedures. We have done 2 angioplasty of immature fistula which led to proper maturation and efficient haemodialysis.

Conclusion: Angioplasty of dysfunctional fistula is efficient procedure in treatment of stenosis or thrombosis. Femoral access to angiography and angioplasty of fistula is promising alternative to other accesses. Angioplasty of immature fistula can lead to proper maturation and efficient haemodialysis.

(NEPROL. DIAL. POL. 2018, 22, 100-103)

Przezskórna przecewnikowa angioplastyka balonowa w leczeniu dysfunkcji przetoki dializacyjnej. Różnice w dostępie naczyniowym

Przezskórna przezcewnikowa angioplastyka jest potwierdzoną i zalecaną metodą leczenia w wielu przypadkach pogarszającej się funkcji tętniczo-żylnej przetoki dializacyjnej. Naszym celem była ocena skuteczności i bezpieczeństwa zabiegu angioplastyki balonowej w przypadku dysfunkcji przetoki dializacyjnej przy użyciu innych niż powszechnie stosowane dostępy naczyniowe.

Materiał i Metodyka: Do zabiegu angiografii zakwalifikowaliśmy 45 pacjentów z dysfunkcją przetoki dializacyjnej, a następnie 37 pacjentów do zabiegu angioplastyki w przypadku stwierdzenia zwężenia lub wykrzepienia przetoki. Każdy zabieg angiografii był wykonywany z dostępu udowego. Skuteczność zabiegu oceniano na podstawie znaczącego przyrostu światła naczynia w obrazie angiograficznym, prawidłowej funkcji przetoki w trakcie dializ w ciągu następnych 12 miesięcy. Podjęto także próbę identyfikacji czynników powodujących dysfunkcję przetoki oraz ewentualne możliwości zapobiegania przyszłej dysfunkcji przetoki dializacyjnej.

Wyniki: Nasze wyniki wykazały, że angiografia i angioplastyka balonowa pogaraszającej się funkcji przetoki dializacyjnej jest wysoce skuteczną oraz bezpieczną dla pacjenta metodą leczenia. W trakcie zabiegów wystąpiły dwa istotne powikłania. Wykonano dwa zabiegi angioplastyki „niedojrzałej" przetoki dializacyjnej, które doprowadziły do prawidłowego „dojrzewania" przetoki oraz efektywnych hemodializ.

Wnioski: Angioplastyka w przypadku dysfunkcji przetoki dializacyjnej jest skuteczną metodą leczenia w przypadku stwierdzenia zwężenia naczynia lub zakrzepicy. Dostęp udowy wykorzystany do angiografii i angioplastyki jest ciekawą alternatywą w porównaniu do innych dostępów. Angioplastyka „niedojrzałej" przetoki dializacyjnej może prowadzić do prawidłowego dojrzewania i skutecznego wykorzystania do hemodializ.

(NEFROL. DIAL. POL. 2018, 22, 100-103)

The authors have no financial interests related to this paper.

Received: 16.09.2018
Accepted: 21.09.2018

Address for correspondence:
Tomasz Nowak
Department of Cardiology, Pomeranian Medical University. Szczecin
ul. Powstancow Wielkopolskich 72, Szczecin, Poland
tel: 723 201 950
e-mail: lek.nowak@gmail.com

Introduction

Chronic kidney disease is currently recognized as a disease of our modern civilization and every year more patients suffer from this illness. The primary method of treatment for this disease is currently haemodialysis. For proper haemodialysis performance, which is sometimes needed two or three times per week, a solid and reliable vascular access is needed that can provide adequate blood flow through the haemodialyzer. In fact, according to the latest NKF-KDOQI guidelines, the best vascular access for haemodialysis is a native arteriovenous fistula. This is the best choice when compared to artificial fistulas or to a catheter, it stays efficient longer, does not restrict the patient's activity, and brings less risk of infection or thromboembolic complications. The maintenance of a well-working dialysis fistula becomes the most important thing for the patient and the nephrologist during haemodialysis. Often the creation of a properly working native fistula is successful after few attempts at the surgical procedure. Using native vessels to create fistulas allows for only a limited number surgical attempts. In spite of the many advantages for haemodialysis of the native dialysis fistula over other vascular accesses methods, they also have some disadvantages. They are, among other things, susceptible to early malfunction in cases of an improperly "matured" native fistula, and later failure due to the many punctures made during dialysis, or as consequence of improper maturation. The most common reason for the above-mentioned complications is stenosis in one of the vessel of the fistula. This often occurs in the vessel in the arteriovenous fistula, causing improper blood flow. One of methods used to treat this disorder is intravascular angioplasty (PTA); this allows the precise reason for the fistula's dysfunction to be diagnosed and enables the implementation of immediate treatment. At present the NKF-KDOQI guidelines recommend intravascular angioplasty as the basic method for treating cases of stenosis in vessels of the arteriovenous dialysis fistula [1-2].

Material and Methods

We qualified 45 patients for an angiography of their dialysis fistula in the period between 13 August 2014 and 24 October 2015 in the Catheter Lab at the Department of Cardiology, Pomeranian Medical University in Szczecin. The qualification criteria for the angiography were as follows: a deteriorated dialysis performance, a sudden inability to perform dialysis, upper limb pain, and lack of "bruit" felt in fistula. The frequency of the occurrences for the respective symptoms is shown in the table below.

In every case the angiographies of the dialysis fistula vessels were done through femoral access, allowing the brachial artery, radial artery, and the arteriovenous anastomosis up to the central vein, to be shown. In cases where stenosis or occlusion of the arteriovenous dialysis fistula were confirmed, patients were qualified at the same time for an intravascular angioplasty to be performed. The angioplasty procedure, due to the location of the stenosis, was done through femoral access; through puncturing the ramus vein in a proximal direction to the fistula (retrograde); or through puncturing the ramus vein in a distal direction from fistula, in line with blood flow (antegrade).

Before the angiography, every patient was administered with 300 mg of acetylsalicylic acid and an optional 600 mg of clopidogrel or 180 mg of ticagrelor; these were only administered if the patient was not taking these drugs before. All angiography and angioplasty procedures were done under antibiotic prophylaxis using 1000 mg of cefazolin i.v., while vascular access was done under local anaesthesia. During the procedures, none of the patient needed general anaesthesia and were only administrated intravenous analgesic drugs – most frequently fentanyl. After the visualisations of the stenoses or occlusions were done, an attempt was made to cross the lesion with an angio-plastic guide-wire. Thereafter a balloon catheter was inserted, depending on the length of the stenosis and the diameter of the vessel, which was then filled with a mixture of Ringer's solution and dye. The maximal pressure used for the balloon catheter during the angioplasty was 30 atmospheres (av. 13.8 atm.). After the procedure a control angiography was done. In a case where a clot occluded the vessel, a thrombectomy system and/or a general or local fibrinolysis through the catheter was used. In order to determine if

Table I
Frequency of respective symptoms dialysis fistula dysfunction.
Częstość poszczególnych objawów dysfunkcji przetoki dializacyjnej.

Dialysis fistula dysfunction symptom	Frequency of respective symptoms in %
Lack of bruit over the fistula	51%
No possibility of dialysis	49%
Deteriorated dialysis performance	16%
Upper limb pain	11%

Table II
Patient characteristic.
Charakterystyka pacjentów.

Patient characteristic:	N = 45
Age (avg.) Sex F/M Other diseases:	61 20/25
Artery hypertension Diabetes type 1	39 1
Diabetes type 2	15
Ischemic heart disease	13
Stroke/TIA	6
Earlier surgical procedures on fistula Earlier radiological procedures on fistula Stenosis in the arteriovenous anastomosis	13 3 34 (75.5%)

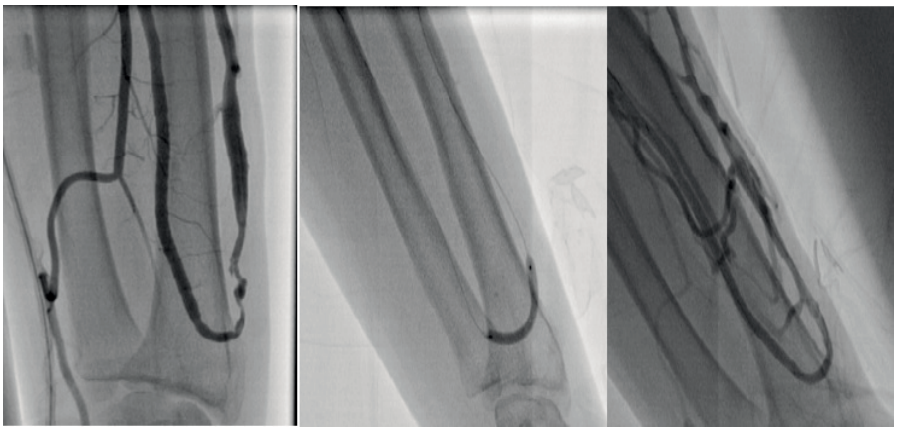

Figure 1
Angiography of a dialysis fistula's vessels and an intravascular angioplasty procedure through femoral access.
Angiografia naczyń tworzących przetokę dializacyjną i zabieg angioplastyki wewnątrznaczyniowej przy wykorzystanie dostępu udowego.

the procedure was successful we needed to observe a significant gain in lumen diameter, with a maximal residual stenosis of 30 %, and no interference to the dye flow in the angiographic evaluation. Every patient was tested for hs-TnT (Troponin T high sensitivity – N < 0.014 µg/l) and D-dimers (N < 500 ng/ml) before, and six hours after, the procedure.

The average time that a fistula was used for dialysis was 22.7 months. The average time between a fistula's creation and the angiography was 12 months. In 73.3% (n=33) of cases the fistula was on the forearm, while in 26.7% (n=12) of cases it was on the upper arm. In 91.1% of cases the fistula was used for dialysis before the angiography. The most common symptoms of fistula malfunction were the lack of bruit in 51% (n=23) of patients; inability to perform dialysis, 40% (n=18); deteriorated dialysis performance, 17.5% (n=8) and localized pain over the fistula, 7.5% (n=3). The average duration for dialysis fistula occlusion in patients qualified for an angiography was 8.7 days. The largest balloon catheter used for an angioplasty was 8 mm in diameter and the biggest inflation pressure was 30 atmospheres. In 6% of cases we used thromboaspiration and in 22% of patients, thrombolysis was administrated after the procedure. The average duration of the procedure was 78.8 minutes, the average time for the fluoroscopy was 23.7 minutes, and the average dose of radiation was 225 mGy.

Results

Of the 45 patients who were qualified for the angiography of their dialysis fistula, 82% (n=37) had the angioplasty procedure. In eight cases we did not perform the angioplasty due to an unsuccessful attempt at crossing the occlusion with a guide-wire (5 instances), an occlusion of the central vein (1), a diagnosis of radial artery dissection (1), or an aneurysmal dilatation of the fistula's venous ramus with the presence of organised clot material. In all cases we performed the angiography using femoral access (n=45); venous access through a puncture in the ramus vein in the proximal direction to the fistula – retrograde (n=5); and through a puncture in the ramus vein in the distal direction from the fistula in line with the blood flow – antegrade (n=3). For the angioplasty procedure we used femoral access in 25 cases, antegrade access in 5 cases and retrograde access in 11 cases. Five patients needed at least two access points for the angioplasty. The angioplasty procedure was successful in 89% (33/37) of cases. Where an occlusion was diagnosed the angioplasty procedure was successful in 80% (16/20) of cases. On the other hand, in the case of a stenosis being diagnosed in the vessel creating the dialysis fistula, but with preserved patency, the angioplasty procedure was successful in 100% (17/17) of patients. In 27 patients (82%), after a successful angioplasty procedure, it was possible for dialysis to be administered through the fistula on the same day or on the day after. In two of the three patients where dialysis had, so far, not been possible, dialysis was possible after the procedure. Primary patency after a successful procedure, with retrospective observation, was as follows: after three months, 77.8%; after six months, 69.2% (18/26); and after twelve months, 36.8% (7/19). The average hs-TnT level in the blood before the angiography was 0.063 µg/l (0.019–0.158) and after was 0.056 µg/l (0.029–0.109). The average D-dimers level in the blood before the procedure was 1648 ng/ml (302–5036) and after was 1046 ng/ml (377–6057). During and after the angioplasty there were two significant complications: one death (not directly related to the procedure), and two pseudoaneurysms of a femoral access site (one of which needed surgical intervention). In the case of the one death, the post-mortem examination ascertained that there had been a penetration of the dialysis catheter introduced through the jugular vein into the pleural cavity; during the administration of thrombolysis there was massive haemorrhage to the pleural cavity; before the procedure the catheter was observed to be located in the central vein according to radiological control. There was no dissection or embolization of the femoral artery during or after the procedure, nor a fistula vessel rupture or pulmonary embolization.

Discussion

The results of the intravascular angioplasty treatment for the failure of the arteriovenous dialysis fistula described above, prove its high efficacy. Recently, many studies have confirmed the high efficacy of intravascular angioplasty in comparison with surgical procedures, which is now reflected in the guidelines concerning the care of vascular access for dialysis (NKF-KDOQI) [1,3]. Angioplasty carries lower stress for patients and a lower risk of complications from infection because of its minimal invasiveness; additionally, after the angioplasty procedure, vascular access through the fistula for dialysis is possible on the same or the next day. The efficacy of angioplasty procedures in our patients is comparable with bibliographical data (89% vs 84.4%–94.6%). Similar results were achieved in the case of full functionality after three months (77.8% vs 82.4%), after six months (69.2% vs 54%–82%) and after twelve months (36.8% vs 44%–72%) [3-10].

In the majority of cases described in the bibliographical data, angiography and angioplasty procedures were performed through a puncture in the brachial artery or through a puncture in the venous ramus of the fistula. In our study we preferred firstly, vascular access to angiography femoral access, and lastly, for angioplasty, depending on the location of the stenosis. The advantage in using femoral access is the possibility of showing all the vessels of the dialysis fistula, from brachial artery through to the central vein. Where there is a suspicion of a fistula occlusion it is possibility to precisely visualize the site of the obstruction and if a stenosis or occlusion in arteriovenous anastomosis is diagnosed, the angioplasty procedure can be done at once. In our study most of the stenoses were located in the arteriovenous anastomosis (75.5%). Another advantage of femoral access is that a haemostasis at the access site or the eventual vasoconstriction after the procedure, did not disrupt the blood flow through the dialysis fistula's vessels. A further advantage of aforementioned access is that in comparison with brachial or radial access there is a lower risk of damaging the brachial or radial artery during or after the procedure. The disadvantage of femoral access is the limited range of regularly used balloon catheters, which forced us to use another vascular access with a higher risk of bleeding from the access site. However, the disadvantage of puncturing the venous ramus is there is then no possibility of visualizing the arteriovenous anastomosis if the fistula has been occluded. Also, if retrograde access is used there is no possibility of penetrating the lesions if it is located on the distal side of the access [7]. In our study, two procedures had pseudoaneurysm complications during femoral access; one of these aneurysms needed surgical intervention and a red blood cell transfusion. Patients with renal failure also have a higher cardiovascular risk; they are often qualified to have a coronarography during the renal transplantation process or because of the high risk of ischemic heart disease. Using femoral access provides an option for performing a coronarography before or after the angioplasty procedure.

Where an angiography diagnoses an immature dialysis fistula with stenosis in the arteriovenous anastomosis or in arterial ramus, the angioplasty procedure may lead to the normal maturation of the fistula in few weeks after the procedure. Many collateral veins in the venous ramus of an immature or malfunctioning arteriovenous fistula make for inadequate blood flow through the main vein and increases the risk of thrombosis. This gives the option of attempting a surgical ligation or the radiological embolization of these collaterals in order to induce the correct maturation of the dialysis fistula and its proper functionality. Oedema of the upper limb with associated failure of the dialysis fistula suggests the stenosis is located in the central vein or nearby.

Conclusion

The failure of a dialysis fistula can be treated effectively using intravascular angioplasty. This method carries a relatively low risk of complications, but has a high rate of success and is less invasive when compared to surgical procedures. Our study shows that femoral access is an interesting alternative strategy for angiography and angioplasty procedures on the dialysis fistula in comparison to the methods of access that are routinely used, but it also has some disadvantages. Ligation or embolization of large collaterals in the fistula's veno-

us ramus can lower the risk of thrombosis and improve the functionality of a mature dialysis fistula, while in an immature fistula it can induce proper maturation; but this is not a routine procedure and still requires more research.

References

1. NKF K/DOQI Clinical Practice Guidelines; Haemodialylisis Access; Internet access; https://www.kidney.org/sites/default/files/11-50-0216_va.pdf
2. **Bojakowski K, Andziak P:** Forearm radiocephalic fistula for dialysis. Acta Angiol. 2011; 17: 117-140.
3. **Miquelin DG, Reis LF, de Silva AA, de Godoy JM:** Percutaneous transluminal angioplasty in the treatment of stenosis of arteriovenous fistulae for hemodialysis. Int Arch Med. 2008, 1:16 doi:10.1186/1755-7682-1-16.
4. **Hansen MA, Gibsholm-Madsen K, Christensen T, Ladefoged SD:** Endovascular treatment of dysfunctional haemodialysis fistulas. Ugeskrift for Laeger 2009; 171: 41-45.
5. **Patanè D, Morale W, Malfa P, Seminara G, Caudullo E. et al:** Steno-obstructions of haemodialytic FAV: new aspects of endovascular treatments. G Ital Nefrol. 2009; 26: 236-245.
6. **Kim WS, Pyun WB, Kang BC:** The primary patency of percutaneous transluminal angioplasty in hemodialysis patients with vascular access failure. Korean Circ J. 2011; 41: 512-517.
7. **Wu CC, Wen SC, Chen MK, Yang CW, Pu SY. et al:** Radial artery approach for endovascular salvage of occluded autogenous radial-cephalic fistulae. Nephrol Dial Transplant. 2009; 24: 2497-2502.
8. **Badero OJ, Salifu MO, Wasse H, Work J:** Frequency of swing-segment stenosis in referred dialysis patients with angiographically documented lesions. Am J Kidney Dis. 2008; 51: 93-98.
9. **Hyun JH, Lee JH, Park SI:** Hybrid surgery versus percutaneous mechanical thrombectomy for the thrombosed hemodialysis autogenous arteriovenous fistulas. J. Korean Surg Soc. 2011; 81: 43-49.
10. **Bountouris J, Kristmundsson T, Dias N, Zdanowski Z, Malina M:** Is repeat PTA of a failing hemodialysis fistula durable? Int J Vasc Med. 2014, Article ID 369687, 6 pages, 2014. doi:10.1155/2014/36968.